

PROSTHETIC REHABILITATION OF A HEMI MANDIBULECTOMY PATIENT WITH TWIN OCCLUSION

Authors:

Tejeswar Reddy B¹
Indira Padmaja B²
Raja Reddy N³

¹Post graduate,
Department of Prosthodontics,
CKS Theja Institute of Dental
Sciences & Research, Tirupathi

²Professor & HOD,
Department of Prosthodontics,
CKS Theja Institute of Dental
Sciences & Research, Tirupathi

³Reader,
Department of Prosthodontics,
CKS Theja Institute of Dental
Sciences & Research, Tirupathi

Address for correspondence:

Dr. B. Tejeswarreddy,
Department of Prosthodontics,
C.K.S. Theja Institute of
Dental Sciences & Research,
Tirupathi 517501,
Andhra Pradesh, India.
Email: b.tejeswarreddy@gmail.com

ABSTRACT

Oral rehabilitation of patients whose mandible and/or adjacent structures are treated with surgery and radiotherapy presents the maxillofacial prosthodontist with a variety of challenges. Resection of mandible may cause topographic defects, physiological and esthetic defects. Mandibular movements are affected with loss of muscle attachments. The most significant difficulty encountered will be deviation of mandible towards the surgical site. Numerous prosthetic methods are employed to minimize deviation and improve efficiency which includes implant supported prosthesis, mandibular guide flange prosthesis, and palatal based guidance restoration. This article describes rehabilitation of patient who underwent hemi mandibular resection with twin occlusion in the maxillary complete denture opposing unresected site of mandible.

Key words: Twin occlusion, hemimandibulectomy

J Odontol Res 2015;3(1)49-53.

INTRODUCTION

Functional rehabilitation of patient who has a partially resected mandible is one of the most challenging procedures confronting the maxillofacial prosthodontist. Loss of continuity of mandible destroys the balance of the mandibular movement and function, leading to altered mandibular movement and deviation of residual fragment towards the surgical side.^{1,2} There are multifactorial causes for the deviation including the extent of osseous and soft tissue involvement, the loss of sensory and motor innervations, the type of wound closure and certain additional forms of treatment that the patient might have received. The greater the loss of tissues, greater will be the deviation of the mandible to the resected side, thus compromising the prognosis of the prosthetic rehabilitation to a greater extent.^{1,2} Apart from deviation other dysfunctions observed are difficulties in mastication, speech, swallowing. Following surgical resection the remaining mandibular segment often is retruded and deviated towards the surgical side at the vertical dimension of rest. During opening deviation increases leading to angular path of opening and closing. Generally in these patients while mastication, entire envelope of motion occurs towards the surgical site which are very less precise.

Canter & Curtis provided a hemimandibulectomy classification for edentulous patients that can be applied in partially edentulous arches^{1,2} (fig. 1). Class I: Mandibular resection involving alveolar defect with preservation of mandibular continuity.

Class II: Resection defects involve loss of mandibular continuity distal to the canine area.

Class III: Resection defect involves loss up to the mandibular midline region.

Class IV: Resection defect involves the lateral aspect of the mandible, but are augmented to maintain pseudo articulation of bone and soft tissues in the region of the ascending ramus.

Class V: Resection defect involves the symphysis and parasymphysis region only, augmented to preserve bilateral temporomandibular articulations.

Class VI: Similar to class V, except that the mandibular continuity is not restored.

Treatment options in such conditions include surgi-

cal reconstruction using alloplastic implants, autogenous bone grafts; allogenic bone graft and prosthetic rehabilitation include mandibular guide flange prosthesis, palatal ramp prosthesis. In patients where reconstruction is not done after resection of the mandible, scar tissue formation occurs over a period of time that stiffens tissues and worsens prosthetic rehabilitation^{3,4}. As patient was completely edentulous, treatment options were very limited.

Factors compromising patient's ability to function with complete dentures are 1. Only half to one third of mandible left compromises stability, retention, support. 2. Angular path of closure induces lateral forces on the dentures that tend to dislodge them. 3. Deviation of mandible creates abnormal jaw relationships. 4. Impairment of motor and sensory control impairs the patient ability to control prosthesis during function. So, this article highlights prosthetic rehabilitation of a hemimandibulectomy patient with twin occlusion.

CASE REPORT

A 68 years old male patient reported to department of prosthodontics with a chief complaint of difficulty in mastication since 3 months. His medical history revealed he is known diabetic and is on medication since 13 years. He underwent mandibular resection and was reconstructed with plating 10 years back in left quadrant region as he was diagnosed with fibrous histiocytoma. But he exhibited a rejection reaction to replating done in mandible so it was surgically removed. His dental history revealed that he underwent extraction of all teeth due to dental caries 3 months back. Extra oral examination revealed that patient has asymmetrical face and convex profile (fig. 2). There was a significant deviation of mandible towards the operated site. Intra oral examination revealed that patient is completely edentulous. On palpation & evaluation of ortho-pantomogram (fig. 3) it was found that mandibular ridge is present till midline. This case represented typical class 3 Cantor and Curtis classification.

CLINICAL PROCEDURE

Preliminary impressions were made with irreversible hydrocolloid material (Zelgan2002, Dentsply) using stock trays (fig. 4). Casts were poured with

type III dental stone (Kalabhai Pvt Ltd, India). On maxillary cast conventional custom tray was fabricated with self-cure acrylic resin (DPI - RR, India) and border molding was performed. Final impression (fig. 5) was made with zinc oxide eugenol impression paste (DPI, Mumbai, India). Mandibular resection results in compromised stability, support and retention. This can be minimized by recording tissue in functional form there by reducing the undue tissue response. Spacer was adapted and nineteen gauge stainless steel wire was bent into loop and placed over spacer. Such two loops were placed. Self cure acrylic resin tray was on the unresected side of mandible. The loops were left open. The tray was finished and polished (fig. 6). Border moulding was on the unresected side and on the resected side impression was made with heavy body putty silicone material (Aquasil, Dentsply). Final impression was made with light body silicone impression material (Aquasil, Dentsply). Impressions were poured with type III dental stone to obtain master cast. Denture bases and wax occlusal rims were fabricated. Maxillary master cast was articulated using a face bow (Hanau USA) on a semi adjustable articulator (Hanau wide vue, USA). Maxillomandibular relation were recorded, patient's tactile sense of comfort was used to assess the vertical dimension of occlusion. Patient was advised to move his mandible as far as possible towards unresected side and gently close his mandible into position to record a functional maxillomandibular relationship (fig. 7). After articulation two sets of semi anatomic teeth were selected⁷. Two rows of teeth were arranged for the posterior region of edentulous maxilla on unaffected side, 1st as per the ridge contour and 2nd palatal to it to occlude with mandibular teeth. Arrangement was verified during try in (fig. 8) and denture was finished and polished in conventional manner (fig. 9). The dentures were evaluated intraorally and the mandible was manipulated to the static centric position area (fig. 10, 11). Any interference in normal movements was corrected. The dentures were removed, repolished and then reinserted. The patient was given post insertion instructions and was motivated to make efforts to learn to adapt to the new dentures. Simple exercises were suggested to the patient such as repeated opening and closing of

mandible. This helped the patient learn to manipulate the lower denture into the proper position. Initially, retention of the dentures, especially the lower one was a problem but this improved with constant use. Within a week, the patient expressed satisfaction in mastication and phonetics.

DISCUSSION

This article highlights functional rehabilitation of hemimandibulectomy patient who has undergone resection without reconstruction. Literature advocates fabrication of guide flange or palatal ramp prosthesis for such patients to prevent deviation of mandible.⁶ Since patient exhibited rejection reaction to the plating done in the mandible it was removed surgically. Since a considerable time had elapsed after surgery guidance flange prosthesis was not possible. Hence we fabricated a conventional maxillary removable partial prosthesis with two rows of teeth-twinning occlusion^{5,7,8}. Two rows of teeth were arranged because the patient could not close in proper intercuspation and hence could not masticate. The palatal row of teeth intercuspated with the remaining mandibular teeth and the buccal row of teeth supported the cheeks. After insertion of the prosthesis the patient could intercuspate mandibular teeth properly due to twin maxillary occlusal table. The patient was kept on 6 months recall. After 1 week the patient reported an increase in masticatory efficiency and seemed happy with the treatment.

CONCLUSION

Surgical and prosthodontic rehabilitation of the mandibulectomy has the potential of being extremely gratifying to clinician as well as to quality of patient's life. Certain basic principles in complete denture fabrication should be modified for mandibular resection patients because of many restrictive physical factors. In edentulous patients, a broad occlusal table developed in the maxillary arch on the unaffected side will help to position the residual fragment into the correct sagittal relationship, enhance the stability of the dentures and thus, improve masticatory ability. The positive thinking about the treatment is that concentration should not be on what is lost in the eradication of disease, but rather taking full advantage of the remaining structures.

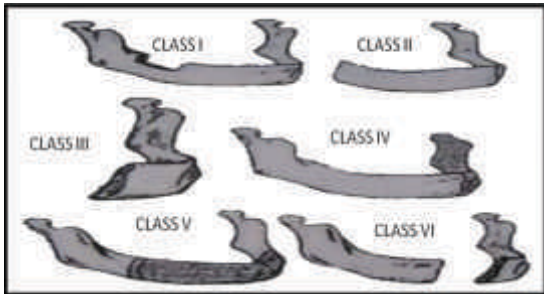


Fig. 1 Canter & Curtis hemimandibulectomy classification

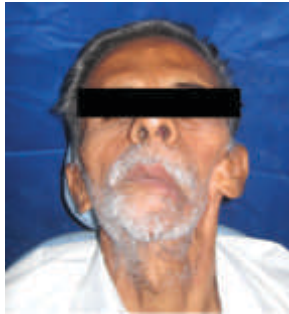

Fig. 2 Extra oral frontal view

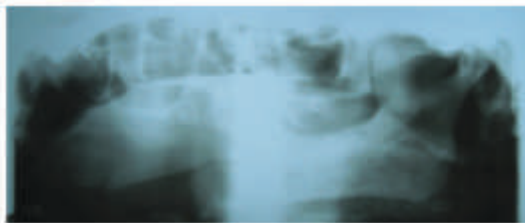


Fig. 3 Ortho-pantomogram revealing resection of mandible

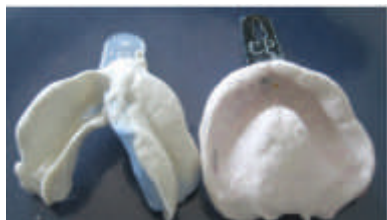

Fig. 4 Preliminary impressions were made with irreversible hydrocolloid material



Fig. 5 Maxillary final impression

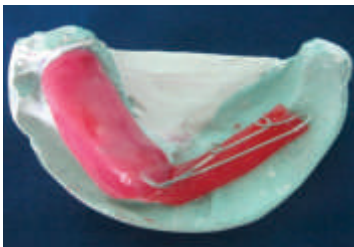

Fig. 6 Finished special tray



Fig. 7 Maxillomandibular relation transferred to semi adjustable articulator

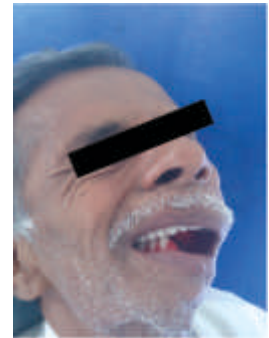
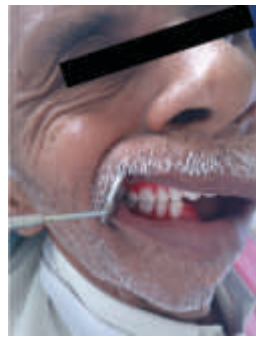
Fig. 8 Twin occlusion try in verified in patients mouth

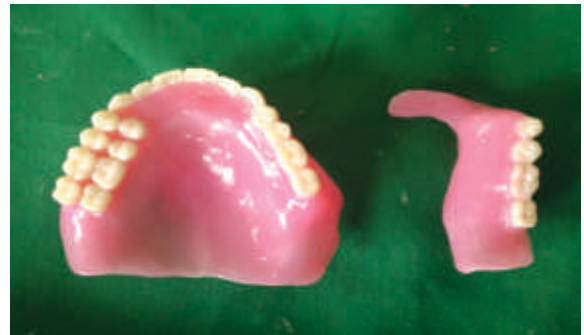

Fig. 9 Finished and Polished maxillary and mandibular dentures

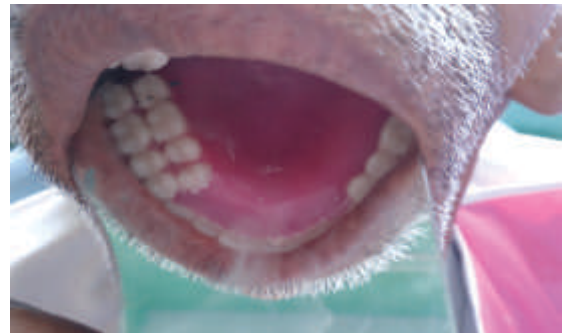


Fig 10 Denture insertion done

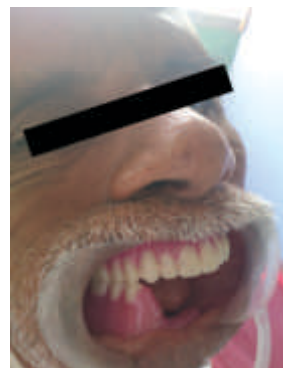


Fig 11 Twin occlusion verified in patients mouth after denture insertion

REFERENCES

1. Beumer J III, Curtis TA, Marunick MT. Maxillofacial rehabilitation: prosthodontic and surgical consideration. Ishiyaku Euro America, St. Louis.1996;184-188.
2. Beumer J, Curtis T, Firtell D. Maxillofacial rehabilitation. St. Louis: Mosby; 1979;90-169.
3. Schneider RL, Taylor TO. Mandibular resection guidance prosthesis: A literature review. J Prosthet Dent. 1986;55:84-6.
4. Swoope CC. Prosthetic management of resected edentulous mandible. J Prosthet Dent. 1969;21:197-202.
5. Scaaf, Oral construction for edentulous patients after partial mandibulectomies. J Prosthet Dent. 1976;36:292-7.
6. Cantor R, Curtis TA. Prosthetic management of edentulous mandibulectomy patients: Part II, Clinical procedures. J Prosthet Dent 1971; 25:546-55.
7. Desjardins RP. Occlusal considerations for the partial mandibulectomy patient. J Prosthet Dent. 1979;41:308-15.
8. Kenneth FB. Complete denture treatment in patients with resected mandible. J Prosthet Dent. 1969;21:443-7.